

Exploring the ability of an AI system to differentiate breast microcalcifications

Presenter: Serena Pacilè

Authors: S. Pacilè, PhD¹, M. Bereby Kahane ,MD², C. Balleyguier, MD³, A. Tardivon, MD² and P. Fillard, PhD¹

¹Therapixel SA, Nice - France

² Department of Imaging, Institut Curie, Paris, FRANCE

³Radiology Department, Institut Gustave Roussy, Villejuif, FRANCE



2021 Disclosures

- S.P. and P.F. are employees at Therapixel

Background

- Calcifications represent an effective indicator for breast cancer
- Nearly 50% of impalpable tumors are detected thanks to the recognition of calcifications¹
- The majority of calcifications present indeterminate characteristics
- The only means to exclude malignancy is biopsy

Purpose

Investigate if AI can:

- Improve the negative predictive value of mammography for calcifications
- Reduce the rate of unnecessary biopsies

¹R. Bonfiglio et al., "Radiological, Histological and Chemical Analysis of Breast Microcalcifications: Diagnostic Value and Biological Significance," J Mammary Gland Biol Neoplasia, vol. 23, no. 1–2, pp. 89–99, Jun. 2018, doi: 10.1007/s10911-018-9396-0.



Materials and Methods

- Retrospective study
- Dataset of 2D Full-Field Digital Mammograms from 5 institutions acquired between 2007 and 2019
- 322 patients who where biopsied because of calcifications
- 108 were diagnosed with cancer
- Comparison between AI system and initial reader in terms of PPV and NPV

AI system:

- MammoScreen v1.2, Therapixel
- Input: 4 views of 2D FFDM
- Output: discrete score from **1** (very low suspicion of malignancy) to **10** (very high suspicion of malignancy)

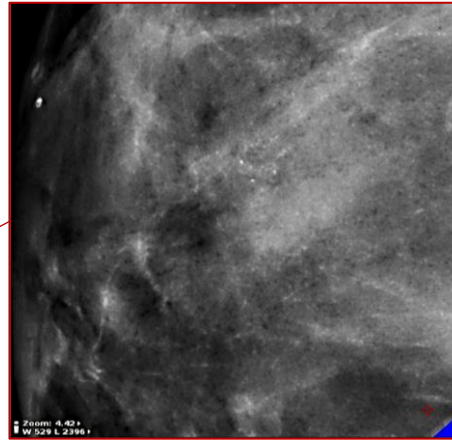
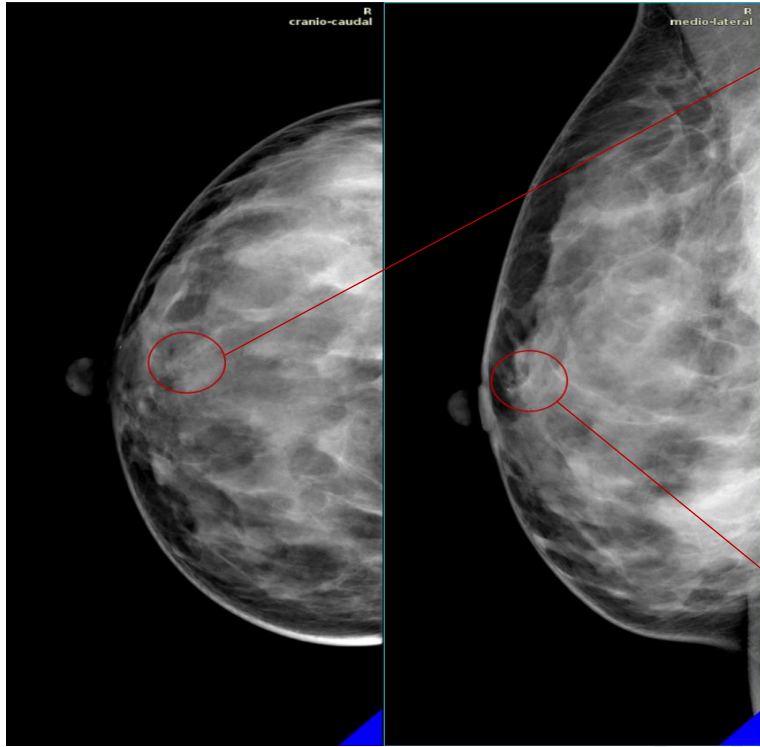


Results

- AI predicted **all** cancers included in the dataset
- PPV = **0.4** (95% CI: 0.38 – 0.42)
- NPV = **0.98** (95% CI: 0.88 – 0.99)
- PPV and NPV significantly **superior** to the original decision
- Rate of unnecessary biopsies reduced by **25%**



Results

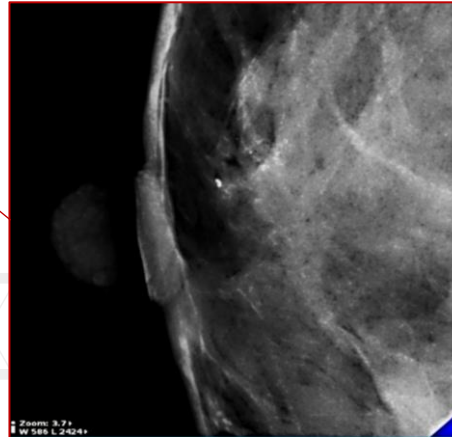


Right CC and MLO mammograms of a patient recalled for biopsy.

Red circles indicate the suspicious area, the right part of the image shows a close-up of the area in the CC and MLO view.

The patient was biopsied three days after the acquisition of this image and the lesion was found to be benign.

AI classified the calcification cluster as **non** suspicious.



Conclusions

The use of this AI system for interpretations of screening mammograms could potentially improve the differentiation of breast microcalcifications while keeping the highest level of sensitivity.



Limitations

- Retrospective
- Small population
- AI system does not process prior examinations



Thank you

Contact: spacile@therapixel.com

